

ORIGINAL RESEARCH

IJPHY

THE COMBINED EFFECTIVENESS OF GLENOHUMERAL END-RANGE MOBILIZATION AND CONTRACT-RELAX TECHNIQUE FOR GLENOHUMERAL INTERNAL ROTATORS IN SUBJECTS WITH ADHESIVE CAPSULITIS

¹Abhijit Kalita²Andrew Milton

ABSTRACT

Background: Frozen shoulder is an insidious condition that begins with pain and gradual restriction of movement in the shoulder region. There are various methods of treating frozen shoulder (both surgical and non-surgical). Among the non-surgical methods there is no specific method accepted universally. Purpose of this study is to determine the combined effectiveness of Glenohumeral End-Range Mobilization and Contract-Relax technique for glenohumeral internal rotators in patients with adhesive capsulitis.

Methods: 60 frozen shoulder patients randomized 30 subjects into each experimental and control group. Group A (experimental group) received Glenohumeral End-Range Mobilization, Contract-Relax Technique for glenohumeral internal rotators and Shoulder Pendular Exercises 2 times a week for a period of 4 weeks (8 sessions). Group B (control group) received Shoulder Pendular exercises 2 times a week for a period of 4 weeks (8 sessions). Outcome measures included are VAS, SPADI and goniometry for assessing pain, functional ability and ROM for the shoulder joint.

Results: The average improvement of VAS for Group A and Group B were 4.5 and 3 respectively using median. The U-value was 176, which is statistically highly significant (p value = 0.000). The average improvement of Shoulder Pain and Disability Index for Group A and group B were 56.9333 and 10.3667 respectively using mean and Standard Deviation. The t-value was 35.91181, which is statistically highly significant (p value = 0.000).

Conclusion: The results indicated that both Group A and Group B had significant improvement in the scores of VAS, SPADI and GONIOMETRY scores at the 4th week when compared to base line values, but when comparing the end results of group A and group B it has been found out that group A intervention is more effective than Group B in treating the internal rotators of patients with adhesive capsulitis

Keywords: Adhesive capsulitis; pain; range of motion; Glenohumeral End-Range Mobilization; Contract-Relax Technique; Shoulder Pendular Exercises.

Received 04th August 2015, revised 29th August 2015, accepted 20th September 2015



www.ijphy.org

DOI: 10.15621/ijphy/2015/v2i5/78221

CORRESPONDING AUTHOR

¹Abhijit Kalita

Senior lecturer,
College of Physiotherapy and Medical
Sciences, Guwahati, Assam.

²Andrew Milton, Vice Principal, Bethany
Navajeevan College of Physiotherapy, Kerala

INTRODUCTION

Adhesive capsulitis (primary) and Frozen Shoulder are current terms used to describe an insidious onset of painful stiffness of the glenohumeral joint.^{1,2,3} and form 2% to 3% of the general population and is the main cause of shoulder pain and dysfunction in individuals aged 40 to 70 years.⁴ Secondary adhesive capsulitis, is associated with a known predisposing condition of the shoulder (e.g. humerus fracture, shoulder dislocation, osteoarthritis).^{4,5,6} and systemic conditions, including cardiovascular disease,⁷ diabetes⁸ and thyroid dysfunction⁹, as well as breast cancer treatment.¹⁰ Even though this condition is considered self-limiting, with most patients having spontaneous resolution within 3 years^{11,12,13} some patients can suffer from long term pain and restricted shoulder motion well beyond 3 years.⁵ The non dominant arm type is mostly affected.^{14,15}

Codman stated that "The condition comes on slowly; pain is felt near the insertion of deltoid; inability to sleep on the affected side; painful and incomplete elevation and external rotation, and a normal radiological appearance."¹⁶ Cyriax proposed predictable pattern of joint restriction (capsular pattern) with lateral rotation most restricted, abduction next most restricted, and medial rotation third most restricted can be seen⁸

Common functional limitations / disabilities seen in frozen shoulder are inability to reach overhead, behind head, out to the side and behind back thus having difficulty in dressing ,reaching hand into back pocket to retrieve wallet, self-grooming and bring eating utensils to the mouth.¹⁷

Stages of Frozen Shoulder ¹⁸ Painful or Freezing Phase typically lasts 10 to 36 weeks¹⁹ with spontaneous onset of shoulder pain, which is often severe and disturbs sleep. Stiffening or Frozen Phase may last 4 to 12 months with restricted ROM in a characteristic pattern of loss of external rotation, internal rotation, and abduction.¹⁸

Thawing Phase is characterized by the gradual recovery of ROM. Which may last an average of 5 to 26 months and is reportedly directly related to the length of duration of the painful phase.¹⁸

Radiographs are usually normal in early stages but done to rule out osteoarthritis, fracture, avascular necrosis, crystalline arthropathy, calcific tendinitis and neoplasm which may restrict movement in the joint. Later changes sometimes show osteopenia, cyst-like changes in the humeral head and joint-space narrowing.²⁰ Arthrography, although invasive, is useful to document decreased joint volume. Normal shoulder joint volumetric capacity

is 28 to 35 mL of injected fluid, whereas in adhesive capsulitis, the joint accepts only 5 to 10 mL.²¹

A variety of treatments have been recommended, with studies demonstrating successful results like non-steroidal anti-inflammatory drugs, local anaesthetic and corticosteroid injections into the glenohumeral joint, calcitonin and antidepressants, distension arthrography, closed manipulation, physical therapy modalities and stretching exercises.²² Identifying the stage of frozen shoulder in which a patient is presenting is important to determine the appropriate treatment regime. Exercise is the key to any treatment protocol for frozen shoulder.² In this study the treatment for frozen shoulder mainly consist of glenohumeral end range mobilization and contract relax technique for glenohumeral internal rotators.

Joint mobilization techniques are assumed to induce various beneficial effects. The neurophysiologic effect is based on the stimulation of peripheral mechanoreceptors and the inhibition of nociceptors. The biomechanical effect manifests itself when forces are directed towards resistance but within the limits of a subject's tolerance. The mechanical changes may include breaking up of adhesions, realigning collagen, or increasing fiber glide when specific movements stress the specific parts of the capsular tissue. Furthermore mobilization techniques are supposed to increase or maintain joint mobility by changes in the synovial fluid, enhanced exchange between synovial fluid and cartilage matrix, and increased synovial fluid turnover.²³

PNF stretching quickens neuromuscular responses by stimulating neural proprioceptors. Proprioceptors are nerve endings found in muscles, tendons and joints which are sensitive to changes in tension. One of these proprioceptors, the Golgi Tendon Organ (GTO) is sensitive to an increase to tension in muscles. When activated the GTO causes the muscle to relax. If this occurs in the same muscle experiencing the increased tension, the result is what we called autogenic inhibition. PNF stretching is very advanced stretching technique and involves a variety of strategies to provide many results. It can be done alone, however it is typically performed with a partner who provides resistance and helps increase the range of motion. The most common technique is the contract-relax method. This method uses a muscle contraction followed by passive stretching. It is usually repeated several times. It is also recommended to mildly stimulate the opposing muscle group in order to return to neuromuscular balance.²⁴

METHODOLOGY

An experimental (comparative study) design conducted over duration of 12 months using paired t test and unpaired t test was done where by using purposive sampling, 60 subjects fulfilling the following criterias were included in the study. Both males and females of age 45-65 years having unilateral involvement with Painful stiff shoulder for at least 3 months. Restriction of more than 50% in passive shoulder external rotation compared to other side and Restricted overhead reach and glenohumeral external rotation when measured at 45° of shoulder abduction were included. Patients having diabetes mellitus, history of surgery on the particular shoulder, rotator cuff rupture or painful stiff shoulder after a serious trauma, fracture of the shoulder complex, presence of osteoarthritis, or signs of bony damage, inflammatory diseases such as rheumatoid arthritis and tendon calcification were excluded.

OUTCOME MEASURES

VAS, SPADI and goniometry was used for assessing pain, functional ability and ROM for the shoulder joint.

PROCEDURE

Subjects were randomly divided into Group A (experimental group) and Group B(control group), each group containing 30 subjects. Pre-test was conducted on Group A and Group B by VAS for assessing pain, goniometer for assessing Glenohumeral active and passive range of motion and SPADI for assessing disability followed by post test for the same after the interventions were implied. The results were recorded and analyzed statistically. Interventions were Glenohumeral End-Range Mobilization, Contract-Relax Technique for glenohumeral internal rotators and shoulder Pendular Exercises was given to Group A subjects 2 times a week for a period of 4 weeks (8 sessions). And Group B subjects did shoulder Pendular exercise 2 times a week for a period of 4 weeks (8 sessions).

End-Range Mobilization:- The technique started with warm up of mid range mobilization with patient in supine. The therapist places his hand on the glenohumeral joint and humerus was brought to position of maximal flexion in sagittal plane. 10-15 repetitions of Maitland mobilization grade 3 or 4 was given in this end range position. Maitland mobilization includes the anterior-posterior glide, posterior-anterior glide and inferior glides respectively. This treatment was given 2 times per week for a period of 4 weeks.

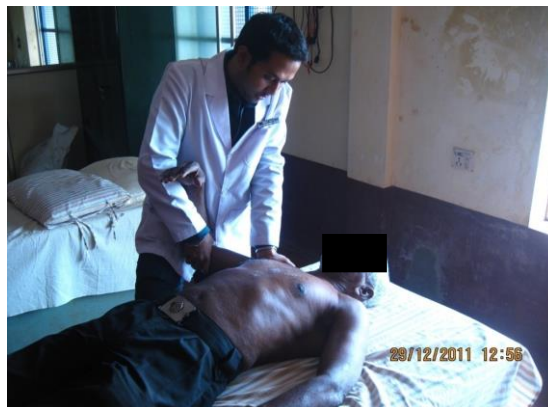

FIGURE 1: ANTERIOR- POSTERIOR GLIDE TO GLENOHUMERAL JOINT

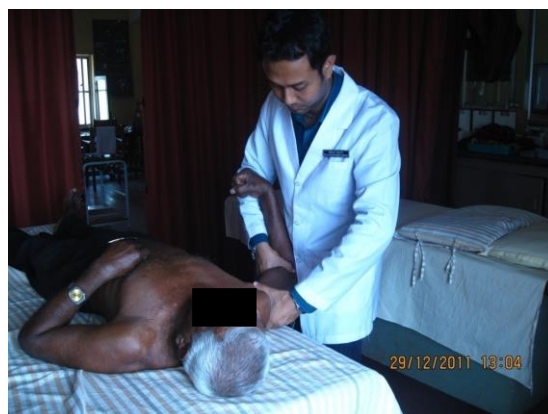

FIGURE 2: INFERIOR GLIDE TO GLENOHUMERAL JOINT

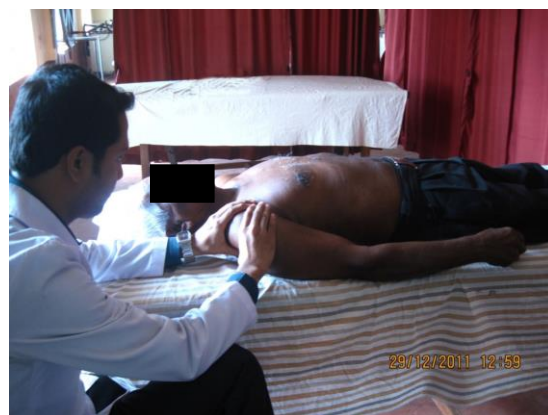

FIGURE 3: POSTERIOR- ANTERIOR GLIDE TO GLENOHUMERAL JOINT

Contract-relax PNF technique:- Patient in supine with humerus was abducted to approximately 45 degree with the elbow flexed to 90 degree, the humerus was externally rotated to a midrange of 20 to 25 degrees. The patient was instructed to perform maximal glenohumeral internal rotation against an opposing, isometric, manual resistance applied by the treating therapist for 7 seconds. Afterwards the patient actively moved the humerus into full available external rotation. This position was maintained for 15 seconds. This 7 sec internal rotation contraction against resistance followed by full active external rotation was repeated 5 times. Subjects were then instructed to

actively move through the PNF flexion-abduction external-rotation diagonal pattern for 5 repetitions with manual facilitation. This treatment was given 2 times per week for a period of 4 weeks.

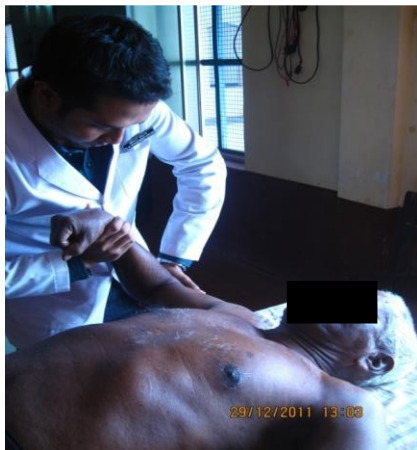

FIGURE 4: PNF TECHNIQUE FOR INTERNAL ROTATORS “CONTRACT RELAX”

Basic Pendular Exercise: Patient used a chair or table for this exercise Patient leaned forward so that his back was near parallel to the floor and his hands were on the back of the chair. The patients firmly gripped the chair with the non affected hand and slowly brought the affected arm down so it hanged freely. Once in this position, the patients slowly swing his affected arm forward, backward and from side to side. These exercises were done in repetition of eight times by the affected hand.

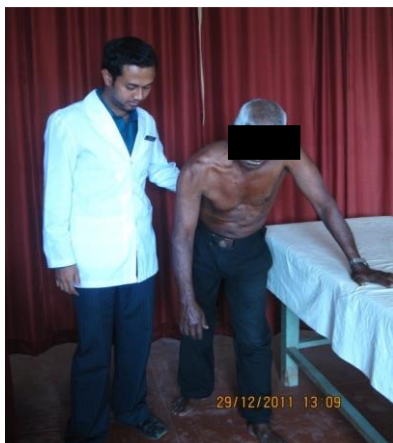

FIGURE 5: SHOULDER PENDULAR EXERCISE

Pendular Circles: This exercise again required the use of the table or chair. Patient got into the position from the basic pendular exercise, leaning against the back of the chair with his affected arm hanging down. Instead of the back and forth movement, this time the patient slowly moves his affected arm in a clockwise circle. His circles were as wide as they can be without pain. Several circles were made with his arm, then stop and switch directions to a counter-clockwise direction. These exercises were done in repetition of 10 times in each direction.

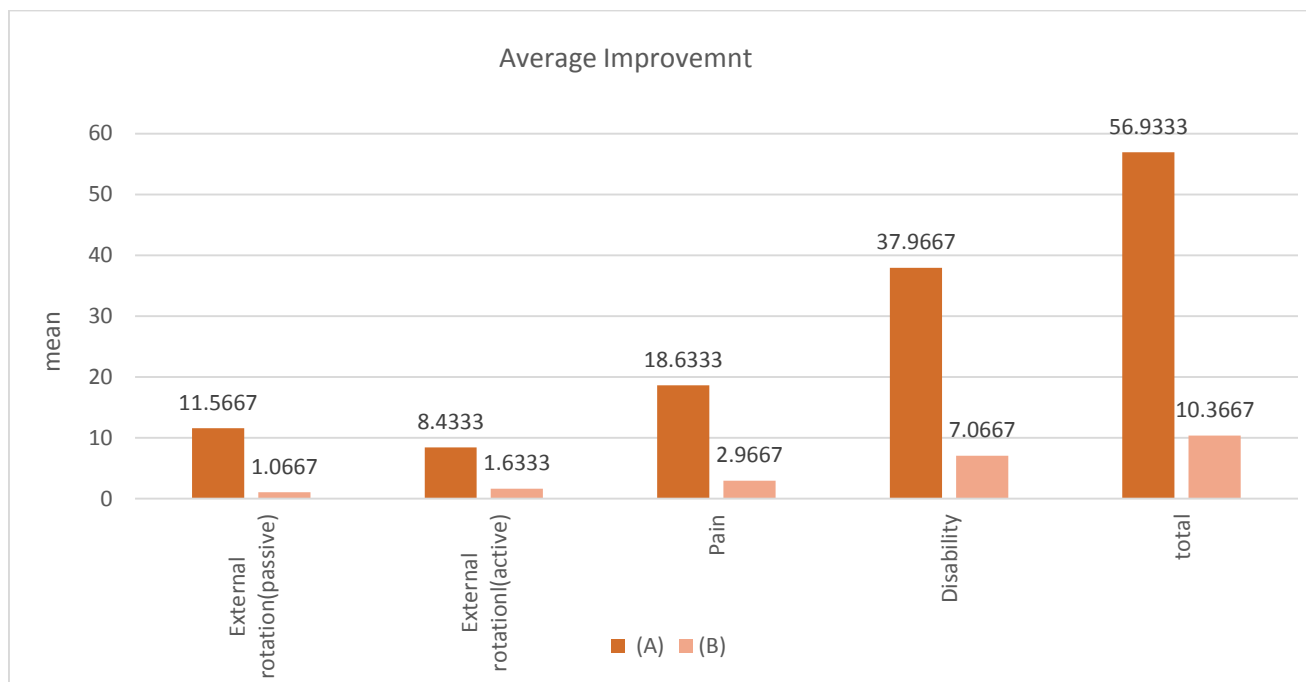
Statistical Methods

Descriptive statistical analysis was carried out in the present study. Outcome measurements analyzed are presented as mean(plus/minus)SD. Significance is assessed at 5% level of significance with p value was set at 0.05 less than this is considered as statistically significant difference. Using purposive sampling; paired t test, Wilcoxon test, and Mannwhitney test, unpaired t test was used to analyze the variables pre-intervention to post-intervention with calculations of percentage of change. The Statistical software namely SPSS16.0,Stata 8.0, Medcalc 9.0.1 and Systat 11.0 were used for the analysis of the data and Microsoft word and Excel have been used to generate the graph, tables etc.

RESULT

| | Average improvement (A) | Average improvement(B) | t-value | p-value | result |
|-----------------------------------|-------------------------|------------------------|----------|---------|--------------|
| External rotation(passive) | 11.5667 | 1.0667 | 9.01117 | 0.000 | P < 0.05 sig |
| External rotation(active) | 8.4333 | 1.6333 | 5.81345 | 0.000 | P < 0.05 sig |
| Pain | 18.6333 | 2.9667 | 16.11825 | 0.000 | P < 0.05 sig |
| Disability | 37.9667 | 7.0667 | 29.93762 | 0.000 | P < 0.05 sig |
| Total | 56.9333 | 10.3667 | 35.91181 | 0.000 | P < 0.05 sig |

Table 1: COMPARISON OF AVERAGE IMPROVEMENT OF EXTERNAL ROTATION (PASSIVE AND ACTIVE), PAIN, DISABILITY AND TOTAL OF SPADI IN GROUP A AND GROUP B.



Graph :1 COMPARISON OF AVERAGE IMPROVEMENT OF EXTERNAL ROTATION (PASSIVE AND ACTIVE), PAIN, DIABILITY AND TOTAL OF SPADI IN GROUP A AND GROUP B.

External Rotation (Passive): The sample size for Group A and Group B was taken as 30 each (N = 30). The comparison of change for External Rotation (Passive) between Group A and Group B were given as: The average improvement for Group A and Group B were 11.5667 and 1.0667 respectively. The t- value was 9.01117, which is statistically highly significant (p = 0.000).

External Rotation (Active): The sample size for Group A and Group B was taken as 30 each (N = 30). The comparison of change for External Rotation (Active) between Group A and Group B were given as: The average improvement for Group A and Group B were 8.4333 and 1.6333 respectively. The t- value was 5.81345, which is statistically highly significant (p = 0.000).

Pain: The sample size for Group A and Group B was taken as 30 each (N = 30). The comparison of change for pain between Group A and Group B were given as: the average improvement for Group A and Group B were 18.6333 and 2.9667 respectively. The t- value was 16.11825, which is statistically highly significant (p = 0.000).

Disability: The sample size for Group A and Group B was taken as 30 each (N = 30). The comparison of change for disability between Group A and Group B were given as: the average improvement for Group A and Group B were 37.9667 and 7.0667 respectively. The t- value was 29.93762, which is statistically highly significant (p = 0.000).

Total score of SPADI: The sample size for Group A and Group B was taken as 30 each (N = 30). The comparison of change for total score of SPADI between Group A and Group B were given as: the average improvement for Group A and Group B were 56.933 and 10.3667 respectively. The t- value was 35.91181, which is statistically highly significant (p = 0.000).

DISCUSSION

In this study it was found that adhesive capsulitis was reported to be more common in women, especially between the ages of 40 to 60 years. This is in accordance to the study done by Neviasser RJ, Neviasser TJ in which they concluded the condition is more prevalent in woman.

This study also reflects that joint mobilization and exercise (pendular exercises) showed beneficial results in the treatment of painfully stiff shoulders which is in accordance with the study done by Garvice G. Nicholson "The effect of Passive joint Mobilization on pain and Hypo mobility associated with Adhesive Capsulitis of the shoulder.

This study proves that Glenohumeral End-Range Mobilization is effective in the treatment of adhesive capsulitis in increasing mobility of the shoulder joint by increasing the Range of motion of the joint. This is in accordance with the similar result obtained by the study performed by Heuricus M Vermeulen, Piet M Rozing et al. (2000) which was End range mobilization techniques in adhesive capsulitis of the shoulder joint²⁷ Likewise in an another randomised clinical trial performed by Jing-lan Yang, Chein-Wei Chang et al. (2007): Mobilization techniques in subjects with frozen shoulder where they included 28 subjects with

frozen shoulder syndrome in the study. The duration of each treatment was 3 weeks for a total of 12 weeks and concluded that End-range mobilization (ERM) and mobilization with movement (MWM) is more effective than mid-range Mobilization (MRM) in increasing mobility and functional ability in subjects with frozen shoulder syndrome.²⁶

In this present study proprioceptive neuromuscular facilitation (contract-relax technique) presented with effective results in the management of patients with adhesive capsulitis. It increases Glenohumeral external rotation and overhead reach in such patients. This is also proved by Joseph Godges J, Melodie matteson – Bell et al. (2003) in their study which was the immediate effect of soft tissue mobilization with proprioceptive neuromuscular facilitation on Glenohumeral external rotation and overhead reach where they included 20 patients with limited glenohumeral external rotation and overhead reach of 1 year duration or less served as subjects. The subjects were randomly assigned to a treatment group, which consisted of soft tissue mobilization to the subscapularis and proprioceptive neuromuscular facilitation (PNF) to the shoulder rotators, or a control group. They concluded that a single intervention session of soft tissue mobilization and proprioceptive neuromuscular facilitation was effective in producing immediate improvements in Glenohumeral external rotation and overhead reach in patient with shoulder disorders.²⁷

In this study for both group A and group B VAS is used for measuring shoulder pain, GONIOMETER for active and passive external rotation range of motion and SPADI for shoulder disability as their validity and reliability are already established.

When Group A and Group B were compared, Group A showed better results than Group B. VAS Scores, Glenohumeral external range of motion Shoulder Pain And Disability Index scores across baseline and post intervention showed a highly significant improvement statistically in their median values within Group A and Group B (p value = 0.000).

CONCLUSION

Glenohumeral End-Range Mobilization, Contract-Relax Technique for glenohumeral internal rotators and shoulder Pendular Exercises was found to be more beneficial when compared to shoulder Pendular exercises in increasing the glenohumeral range of motion and reducing VAS and disability (Shoulder Pain And Disability Index) scores at 4th week (post intervention) when compared to pre intervention values in patients

with adhesive capsulitis, so it is evident that above set of treatment protocol can be used as an effective treatment intervention in the patients with adhesive capsulitis.

LIMITATION

Further studies can be carried out in patients with secondary adhesive capsulitis due to diabetes mellitus, or any surgery related to thorax or shoulder. Duration of the study can be increased beyond 12 months to find out the long term efficacy of the treatment intervention.

ACKNOWLEDGEMENTS

The author would like to thank all the people who helped and encouraged him for the guidance and completion of this study. Dr. Lavanya N Suvarna, Lecturer, Dr. M. V. Shetty College of Physiotherapy for her constant guidance, inspiration, encouragement and generous cooperation at every step of this study. Dr. S. Earnest Jacob, Principal, Dr. M. V. Shetty College of Physiotherapy for his help and advice. Dr. U. T Ifthikar Ali, Professor, Dr M. V. Shetty College of Physiotherapy for his constant support and encouragement. A special thanks to Dr Vinod Babu K, Assistant professor, KTG college of Physiotherapy, Bangalore and Dr Kritica Boruah, lecturer, College of Physiotherapy and Medical Sciences, Guwahati for their suggestions and guidance.

Conflict Of Interest: None

REFERENCES

1. Baslund B, Thomsen BS, Jensen EM. Frozen shoulder: current concepts. *Scand J Rheumatol.* 1990;19(5):321-5.
2. Cyriax J. *Textbook of Orthopedic Medicine.* 8th ed. London, UK: Baillière Tindall; 1982.
3. Neviasser RJ, Neviasser TJ. The frozen shoulder. *Diagnosis and management.* *Clin Orthop Relat Res.* 1987 Oct;(223):59-64.
4. Mao CY, Jaw WC, Cheng HC. Frozen shoulder: correlation between the response to physical therapy and follow-up shoulder arthrography. *Arch Phys Med Rehabil.* 1997;78(8):857-9.
5. Shaffer B, Tibone JE, Kerlan RK. Frozen shoulder. A long-term follow-up. *J Bone Joint Surg Am.* 1992; 74(5):738-746.
6. Siegel LB, Cohen NJ, Gall EP. Adhesive capsulitis: a sticky issue. *Am Fam Physician.* 1999; 59(7):1843-1852.
7. Minter WT III: The shoulder-hand syndrome in coronary disease. *J Med Assoc Ga.* 1967; 56(2):45-49.
8. Cyriax J. *Textbook of Orthopedic Medicine, Vol 1: Diagnosis of Soft Tissue Lesions.* 7th ed; 1978.

9. Wohlgethan JR: Frozen shoulder in hyperthyroidism. *Arthritis Rheum.* 1987; 30 (8):936-939.
10. Cheville AL, Tchou J: Barriers to rehabilitation following surgery for primary breast cancer. *J Surg Oncol.* 2007;95(5):409-418
11. Grey RG. The natural history of "idiopathic" frozen shoulder. *J Bone Joint Surg Am.* 1978; 60(4):564.
12. Griggs SM, Ahn A, Green A. Idiopathic adhesive capsulitis. A prospective functional outcome study of nonoperative treatment. *J Bone Joint Surg Am.* 2000; 82-A(10): 1398-1407.
13. Loew M, Heichel TO, Lehner B. Intraarticular lesions in primary frozen shoulder after manipulation under general anesthesia. *J Shoulder Elbow Surg.* 2005; 14(1):16-21.
14. Hand C, Clipsham K, Rees JL, Carr AJ: Long-term outcome of frozen shoulder. *J Shoulder Elbow Surg.* 2008; 17(2):231-236.
15. Levine WN, Kashyap CP, Bak SF, Ahmad CS, Blaine TA, Bigliani LU: Nonoperative management of idiopathic adhesive capsulitis. *J Shoulder Elbow Surg.* 2007; 16(5):569-573.
16. Cheville AL, Tchou J: Barriers to rehabilitation following surgery for primary breast cancer. *J Surg Oncol.* 2007;95(5):409-418.
17. Hannafin JA, Strickland SM, Frozen shoulder syndrome. *Scand J Rheumatol.* 1976; 4:193-6.
18. Cyriax J: The shoulder, *Br J Hosp Med:* 185-192, 1975
19. Reeves B: The natural history of frozen shoulder syndrome. *Scand J Rheumatol.* 1975;4(4):193-6.
20. Lori B. Siegel, Norman J. Cohen, Eric P. Gall. Adhesive Capsulitis: A Sticky Issue. *Am Fam Physician.* 1999 Apr 1;59(7):1843-1850.
21. Neviasser JS: Arthrography of the Shoulder: The Diagnosis and Management of the Lesions Visualized. 1976;63(4):335.
22. Rizk TE, Gavant ML, Pinals RS. Treatment of adhesive capsulitis (frozen shoulder) with arthrographic capsular distension and rupture. *Arch Phys Med Rehabil.* 1994 ;75(7):803-7.
23. Carolyn Kishner, Lyhn Allen Colby. Therapeutic exercise. Foundations, third edition. Page 190-191.
24. Holcomb WR. Stretching using PNF: written for the use of American college of sports medicine. USOC Olympic coach E-Magazine 2002.
25. Henricus M Vermeulen, Wim R Obermann, Bart J Burger, Gea J Kok, Piet M Rozing, Cornelia HM van den Ende. End-Range Mobilization Techniques in Adhesive Capsulitis of the Shoulder Joint: A Multiple-Subject Case Report. *Phys Ther.* 2000; 80(12):1204-1213.
26. Jing-lan Yang, Chein-wei Chang, Shiau-yee Chen, Shwu-Fen Wang, Jiu-jenq Lin. Mobilization Techniques in Subjects With Frozen Shoulder Syndrome: Randomized Multiple-Treatment Trial. *Phys Ther.* 2007; 87(10):1307-1315
27. Joseph J. Godges, Melodie Mattson-Bell, Donna Thorpe, Drashti Shah. The immediate effect of soft tissue mobilization with proprioceptive neuromuscular facilitation on Glenohumeral external rotation and overhead reach. *J Orthop Sports Phys Ther.* 2003 ;33(12):713-8.

Citation

Abhijit kalita, & Andrew Milton. (2015). THE COMBINED EFFECTIVENESS OF GLENOHUMERAL END-RANGE MOBILIZATION AND CONTRACT-RELAX TECHNIQUE FOR GLENOHUMERAL INTERNAL ROTATORS IN SUBJECTS WITH ADHESIVE CAPSULITIS. *International Journal of Physiotherapy*, 2(5), 691-697.