

## ORIGINAL ARTICLE

IJPHY

## A COMPARATIVE STUDY ON THE EFFECT OF PARAFFIN WAX THERAPY WITH MANUAL MOBILIZATION VERSUS ULTRASOUND THERAPY WITH MANUAL MOBILIZATION ON PAIN, RANGE OF MOTION AND FUNCTIONAL STATUS OF SHOULDER IN DIABETIC SUBJECTS WITH ADHESIVE CAPSULITIS

<sup>1</sup>Dr. A. Viswanath Reddy<sup>2</sup>Dr. S. Raghava Krishna<sup>3</sup>Dr. K. Madhavi<sup>4</sup>Dr. Alok Sachan

## ABSTRACT

**Background:** The shoulder is a complex joint that plays a crucial role in many activities of daily living. Adhesive capsulitis is defined as a painful and disabling condition in which the capsule and the connective tissue surrounding the glenohumeral (GH) joint becomes inflamed, leading to restriction of range of motion in the joint. A wide range of physical therapy interventions are used to improve the joint range of motion in subjects with adhesive capsulitis. Earlier, isolated studies were done on the effectiveness of paraffin wax therapy and ultrasound therapy in subjects with adhesive capsulitis. The need of the present study was to compare the effect of paraffin wax therapy with manual mobilization and ultrasound therapy with manual mobilization on pain, shoulder ROM and functional status in diabetic subjects with adhesive capsulitis.

**Methods:** Subjects for the study were recruited from the outpatient department of endocrinology and physiotherapy. The size of the sample is 80 (eighty subjects) 40 in each group and study design is an experimental study design (Non-randomized open-label).

The pretreatment values of pain and functional status of the shoulder were assessed using Shoulder Pain and Disability Index (SPADI) scale and ROM was assessed using a universal goniometer. The subjects in paraffin wax therapy group received wax therapy for 10 minutes and undergone manual mobilization. The subjects in the ultrasound therapy group received ultrasound therapy (3MHz) for 10 minutes and undergone manual mobilization. The treatment was given for 3 sessions per week for a 6 weeks and post treatment values were noted for the subjects of both the groups.

**Results:** There was an improvement of ROM of external rotation, pain & functional status of the shoulder in subjects who underwent paraffin wax therapy with mobilization and ultrasound therapy with mobilization. When comparing both the groups, the subjects who underwent paraffin wax therapy with mobilization have better outcomes than ultrasound therapy with the mobilization group ( $p < 0.05$ ).

**Conclusion:** There was an improvement of ROM of external rotation, pain & functional status of the shoulder in subjects who underwent paraffin wax therapy with mobilization and ultrasound therapy with mobilization. When comparing both the groups, the subjects who underwent paraffin wax therapy with mobilization have better outcomes than ultrasound therapy with the mobilization group.

**Keywords:** Adhesive capsulitis, Paraffin wax therapy, Ultrasound therapy, Mobilization, Range of motion, Functional status.

Received 08<sup>th</sup> August 2019, accepted 03<sup>rd</sup> October 2019, published 09<sup>th</sup> October 2019



www.ijphy.org

10.15621/ijphy/2019/v6i5/186842

<sup>2</sup>Lecturer, College of Physiotherapy,  
Sri Venkateswara Institute of Medical Sciences,  
Tirupati 517501, Andhra Pradesh, India.

<sup>3</sup>Professor, College of Physiotherapy,  
Sri Venkateswara Institute of Medical Sciences,  
Tirupati 517501, Andhra Pradesh, India.

<sup>4</sup>Professor, Department of Endocrinology  
Sri Venkateswara Institute of Medical Sciences,  
Tirupati 517501, Andhra Pradesh, India.

## CORRESPONDING AUTHOR

<sup>1</sup>Dr. A. Viswanath Reddy

Associate Professor  
College of Physiotherapy  
Sri Venkateswara Institute of Medical Sciences,  
Tirupati 517501, Andhra Pradesh, India.  
email: avilalaviswanath@gmail.com

## INTRODUCTION

The shoulder is a complex joint that plays a crucial role in many activities of daily living. Adhesive capsulitis is defined as a painful and disabling condition in which the capsule and the connective tissue surrounding the glenohumeral (GH) joint becomes inflamed leading to restriction of range of motion in the joint [1].

Adhesive capsulitis was first described by Duplay (1872) and in 1934, Codman first proposed the term Frozen shoulder. It is characterized by insidious and progressive pain and loss of both active and passive range of motion of GH joint due to development of dense adhesions and capsular restriction in the dependent fold of the capsule of GH joint [2].

The annual incidence is 2%, and of this 20-30 % will go on to develop the condition bilaterally. It is more common in females, age over 40 years and in the non-dominant arm [2].

Adhesive capsulitis is associated with a global dysfunction of the involved extremity. The functional limitations/ disabilities seen in subjects with adhesive capsulitis are the inability to reach overhead, behind head, out to the side and behind back thus having difficulty in dressing in men and women according to its severity.

Bridgman reviewed the medical records of 800 diabetic subjects and found evidence of 10.8%, compared to 2.3% in a control group of 600 non-diabetic subjects. The prevalence of limited joint mobility in subjects with diabetes mellitus has varied from 8 to 42% [3].

According to Kim (2000), diabetic subjects are much more likely to have a problem with the mobility in the shoulders than others, with a loss of about 50 % of shoulder mobility.<sup>4</sup>

According to American Diabetic Association (ADA), collagen, one of the building blocks of ligaments and tendons holds the bones together in a joint. Glucose (sugar) molecules attach to the collagen. In diabetic subjects, abnormal deposition of collagen in the cartilage and tendons of the shoulder results in stiffness of the joint. Calcium spots in the tendons and muscles around the shoulder are also seen more commonly in diabetic subjects can impair blood flow through small vessels and limit mobility [5].

The majority of subjects respond to a regular exercise program, and physical therapy plays a vital role in these subjects. Extensive use of non-steroidal anti inflammatory drugs is not recommended. In physical therapy, many interventions are used which include heat or ice application, Ultrasound therapy, TENS, active and passive ROM exercises and mobilization techniques.

Mobilizations are low velocity skilled passive movements performed by the clinician to an affected joint within or at the limits of joint range of motion at speed slow enough that the subject can stop the movement [6].

A wide range of physical therapy interventions is used to improve the joint range of motion in subjects with adhesive capsulitis. Earlier, isolated studies were done on the

effectiveness of paraffin wax therapy and ultrasound therapy in subjects with adhesive capsulitis. The need for the present study was to compare the effect of paraffin wax therapy with manual mobilization and ultrasound therapy with manual mobilization on pain, shoulder ROM and functional status in diabetic subjects with adhesive capsulitis.

The study aimed to compare the effect of paraffin wax therapy with manual mobilization and ultrasound therapy with manual mobilization on pain, ROM and functional status of shoulder in diabetic subjects with adhesive capsulitis.

The objectives of the study were to analyze the pain and functional status of shoulder using Shoulder Pain and Disability Index (SPADI) scale and range of motion using universal goniometer in subjects undergoing paraffin wax therapy along with manual mobilization and in subjects undergoing ultrasound therapy along with manual mobilization and compare the effects between both the groups.

## MATERIALS AND METHODOLOGY

**Study setting:** Subjects for the study were recruited from the outpatient department of endocrinology and physiotherapy.

**Sample size:** 80 (eighty subjects) 40 in each group.

Sample size is calculated by using the following formula:  
$$N = 2 \times (Z_{\alpha/2} + Z_{\beta})^2 \times (S.D)^2 / (Diff)^2$$

Where  $Z_{\alpha/2} = 1.96$  to  $P < 0.05$ ;  $Z_{\beta} = 0.84$  for power of 80 % with  $S.D = 1.75$  and Difference of 80%, sample size is estimated as 74.97.

**Study design:** Experimental study design (Non-randomized open-label study)

**Inclusion criteria:** Subjects diagnosed to be having diabetes mellitus on the American Diabetic Association (ADA) criteria of 2010 ( Fasting plasma glucose > 126 mg/dl or Post 75 gm glucose > 200 mg/dl or HbA1c > 6.5% -one of these on two different occasions) or being on anti-diabetic medication with adhesive capsulitis. The subjects diagnosed with primary idiopathic adhesive capsulitis who are adults below the age of 65 years with unilateral involvement were included in the study.

**Exclusion criteria:** Subjects who underwent manipulation under anesthesia, who have administered intra-articular steroidal injections and subjects suffering from disorders of cervical spine, Psychiatric conditions, neurological disorders such as stroke, Parkinson's disease affecting shoulder were excluded from the study.

**Ethical clearance:** The study was approved by the Institutional ethics committee of SVIMS, Tirupati (IEC No.502) date: 13-02-2016.

The materials such as universal goniometer, paraffin wax therapy, ultrasound therapy, high couch, and stabilization pads were used for the study.

The purpose of the study was explained to the subjects, and written informed consent was taken from all the subjects. They were instructed to come to physiotherapy outpatient

department for the treatment. After collecting the demographic data as per the attached proforma, the subjects were randomly assigned to two groups, i.e., paraffin wax therapy with manual mobilization group and ultrasound therapy with manual mobilization group.

The pre-treatment values of pain and functional status of the shoulder were assessed using Shoulder Pain, and Disability Index (SPADI) scale and ROM were assessed using universal goniometer.

The subjects in the paraffin wax therapy group received wax therapy for 10 minutes and undergone manual mobilization. The subjects in ultrasound therapy group received ultrasound therapy (3MHz) for 10 minutes and undergone manual mobilization.

Manual mobilization of shoulder mainly constituted arthrokinematic movements such as rolling and gliding movements of the humeral head on the glenoid fossa with proper stabilization of the scapula in lying and sitting positions. Manual mobilization was given for the subjects of both the groups after paraffin wax therapy or ultrasound therapy for about fifteen minutes.

The treatment was given for three sessions per week for six weeks, and post-treatment values were noted for the subjects of both the groups.

Statistical analysis: Comparison of means between baseline and post-treatment measurements was done by the paired t-test and comparison of means between the groups at baseline and following treatment was done by the unpaired t-test or Mann Whitney U-test. p-value < 0.05 was taken as significant. Tabulating the data was done using Microsoft Excel spreadsheets, and statistical analysis was done using the SPSS 21.0 version.

## RESULTS

After the data analysis, the obtained results were tabulated as follows.

**Table 1:** Demographic data of subjects of both the groups.

Name of the group	No. of Males	Mean age	No. of Females	Mean age
Wax therapy group and mobilization group (N=36)	20	58.4	16	54.56
Ultrasound therapy and mobilization group (N=36)	21	62.9	15	56.06

**Table 2:** Pre and Post values of external rotation and SPADI scores in wax therapy and mobilization group.

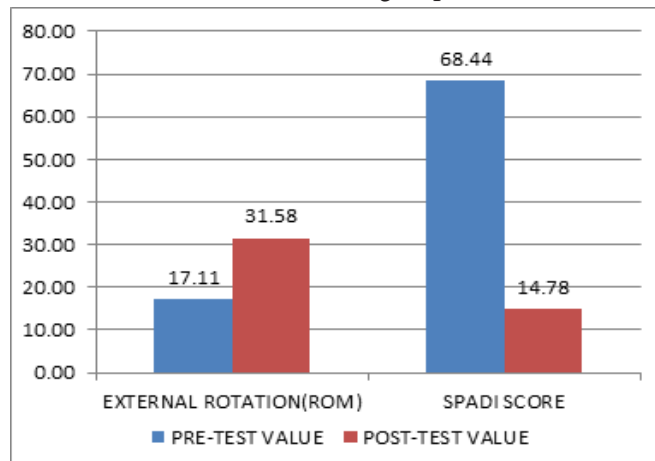
WAX THERAPY AND MOBILIZATION GROUP (N=36)						
	PRE-TEST VALUE		POST-TEST VALUE		t-value	p-value
	Mean	S.D	Mean	S.D		
EXTERNAL ROTATION (ROM)	17.11	4.46	31.58	4.53	43.89	0.00
SPADI SCORE	68.44	6.1	14.78	3.08	74.15	0.00

Results: The pre-value of mean and standard deviation of external rotation is 17.11±4.46 and post value is 31.58

± 4.53. The pre-value of mean and S.D of SPADI score is 68.44 ± 6.1, and post value is 14.78 ± 3.08.

Inference: The ROM of external rotation and the functional status of the shoulder was improved after the wax therapy and mobilization.

**Figure 1:** The graph showing the pre and post values of external rotation and SPADI scores in wax therapy and mobilization group.



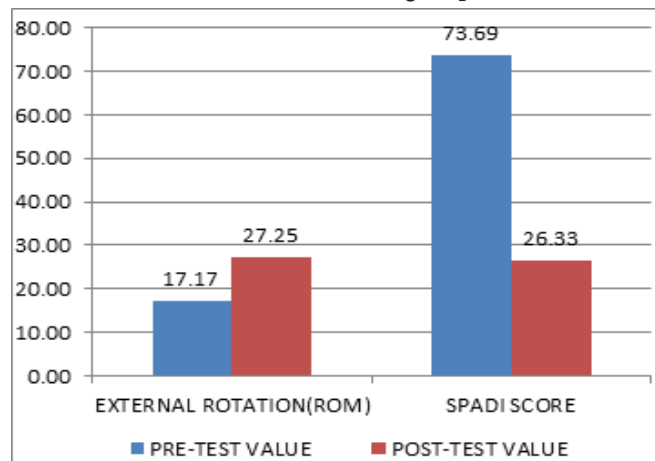
**Table 3:** Pre and Post values of external rotation and SPADI scores in ultrasound therapy and mobilization group.

ULTRASOUND THERAPY AND MOBILIZATION GROUP (N=36)						
	PRE-TEST VALUE		POST-TEST VALUE		t-value	p-value
	Mean	S.D	Mean	S.D		
EXTERNAL ROTATION (ROM)	17.17	4.19	27.25	3.88	37.57	0.00
SPADI SCORE	73.69	6.56	26.33	4.54	85.10	0.00

Results: The pre value of mean and standard deviation of external rotation is 17.17±4.19 and post value is 27.25 ± 3.88. The pre value of mean and S.D of SPADI score is 73.69 ± 6.56 and post value is 26.33 ± 4.54.

Inference: The ROM of external rotation and the functional status of the shoulder was improved after the ultrasound therapy and mobilization.

**Figure 2:** The graph showing the pre and post values of external rotation and SPADI scores in ultrasound therapy and mobilization group.



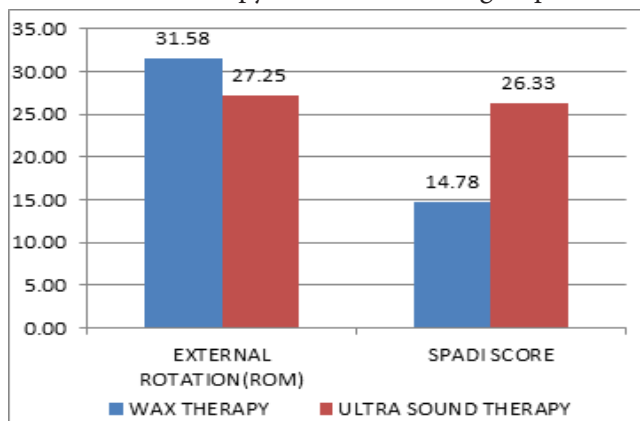
**Table 4:** Comparison of post values of external rotation and SPADI scores in wax therapy and mobilization with ultrasound therapy and mobilization group.

	ULTRA SOUND THERAPY AND MOBILIZATION GROUP (n=36)		WAX THERAPY AND MOBILIZATION GROUP (n=36)		t-value	p-value
	Mean	S.D	Mean	S.D		
EXTERNAL ROTATION (ROM)	27.25	3.88	31.58	4.53	4.00	0.00
SPADI SCORE	26.33	4.54	14.78	3.08	13.18	0.00

Results: The post values of the mean and standard deviation of external rotation are  $27.25 \pm 3.88$  and  $31.58 \pm 4.53$  in wax therapy and ultrasound therapy groups respectively. The post values of mean and S.D of SPADI score are  $26.33 \pm 4.54$  and  $14.78 \pm 3.08$  in wax therapy and ultrasound therapy groups respectively.

Inference: The ROM of external rotation and the functional status of the shoulder was improved well in subjects of wax therapy and mobilization group when compared to the ultrasound therapy and mobilization group.

**Fig 3:** Graph showing post values of external rotation and SPADI scores in wax therapy and mobilization with ultrasound therapy and mobilization group.



## DISCUSSION

In this study, the subjects diagnosed with adhesive capsulitis were randomly allocated to two groups, namely paraffin wax therapy and ultrasound therapy. Manual mobilization was given for subjects of both the groups after the electrotherapy treatment.

Physiotherapy modalities play an important role in decreasing the pain in the subjects with adhesive capsulitis. The mobilization techniques administered by the physiotherapist have proved to enhance the mobility of the shoulder joint thereby helping in the improvement of functional ability of the upper limb. The arthrokinematic movements such as rolling and gliding in the glenohumeral joint might have improved after the mobilization techniques which lead to the enhanced range of motion of the shoulder joint.

The results of table 2 reveal that there was reduction of pain, improvement of the ROM of external rotation & functional status of the shoulder after the wax therapy and mobilization. Paraffin wax therapy helps in loosening the

adhesions, and the mobilization helps in breaking the adhesions of the glenohumeral joint aiding in the improvement of ROM and functional status of shoulder.

A study was done by Fozia Sibtain et al. (2013) on 71 subjects in post-traumatic stiff hand concluded that paraffin wax therapy combined with joint mobilization techniques are more effective in the physical therapy rehabilitation of post-traumatic stiff hand as compared to joint mobilization techniques alone [7].

Adhesive capsulitis is characterized by insidious and progressive pain and loss of both active and passive range of motion of the glenohumeral joint due to the development of dense adhesions and capsular restriction in the dependent fold of the capsule. As symmetrical capsular tightness has the potential to impact humeral head motion and hence gliding movements given during mobilization helps in reducing the capsular tightness and aid in the improvement of the range of motion.

The results of table 3 reveal that there was reduction of pain, improvement of the ROM of external rotation & functional status of the shoulder after the ultrasound therapy and mobilization. According to Cameron, ultrasound therapy with a low average intensity has been shown to increase intracellular calcium, increase skin and cell membrane permeability, increase mast cell degranulation and increase in the rate of protein synthesis by fibroblasts.

The results of table 4 reveal that there was a reduction of pain, improvement of the ROM of external rotation & functional status of the shoulder in the subjects of paraffin wax therapy and mobilization group than that of the ultrasound therapy and mobilization group. Earlier studies reveal that the paraffin wax therapy acts as type of thermotherapy that helps to increase blood flow, relax muscles and reduce the stiffness in the joints.

A study was done by Nicholson (1985) on the effect of joint mobilization on pain and hypomobility associated with patients suffering from adhesive capsulitis found that all ranges of the shoulder improved significantly after the treatment [8].

According to Carolyn Wards worth, passive exercises result in multiple benefits. Gentle passive exercises short of pain and the pathological limit of motion reduce pain. Theoretically, this pain reduction occurs due to neuromodulation effect on the mechanoreceptors within a joint [9].

Hence, in this study, manual mobilization also aided in the improvement of ROM of shoulder following the treatment done using electrotherapy modalities.

## CONCLUSION

There was a reduction of pain, improvement of ROM of external rotation & functional status of the shoulder in subjects who underwent paraffin wax therapy with mobilization and ultrasound therapy with mobilization. When comparing both the groups, the subjects who underwent paraffin wax therapy with mobilization have better outcomes than the ultrasound therapy with mobilization group.

---

## REFERENCES

- [1] Zuckerman JD, Rokito A. Frozen shoulder: A consensus definition. *Journal of shoulder and elbow surgery*. 2011; 20(2):322-325.
- [2] Neviasser AS, Hannafin JA. Adhesive capsulitis: a review of current treatment. *American Journal of sports medicine*.2010;38:2346-2356.
- [3] J.F. Bridgman. Periarthritis of the shoulder and diabetes mellitus. *Journal of Annals of the Rheumatic diseases*. 1972; 31(1): 69-71.
- [4] Kim N.H. et al. Serum ferritin in healthy subjects and type 2 diabetic patients. *Yonsei Med Journal*. 2000;41 (3); 387-92.
- [5] Connie B.Tighe, et al. The prevalence of a diabetic condition and adhesive capsulitis of the shoulder. *Southern medical journal*. 2008; 101 (6): 591-5.
- [6] Scott Buxton, Kim Jackson et al., Maitland mobilizations, [www.Physio-pedia.com](http://www.Physio-pedia.com).
- [7] Fozia Sibtain et al. Efficacy of paraffin wax bath with and without joint mobilization techniques in rehabilitation of post-traumatic stiff hand. *Pak.J Med Sci*. 2013; 29 (2): 647-650.
- [8] Nicholson GG. Effect of joint mobilization on pain and hypomobility associated with patients suffering with adhesive capsulitis. *Journal of orthopedics and sports physical therapy*. 1985; 6 (4) :238-246.
- [9] Wadsworth C.T (1986): Frozen shoulder. *Physical therapy*. 1986; 66 (12): 1878-1883.