

ORIGINAL ARTICLE

IJPHY

CORRELATION BETWEEN UPPER TRAPEZIUS, LEVATOR SCAPULAE AND PECTORALIS MINOR MUSCLE LENGTH IN FROZEN SHOULDER – A CROSS-SECTIONAL OBSERVATIONAL STUDY

^{*1}Pranisa Vardanapu¹Naga Sravana Kumar Jampa²Asif Hussain

ABSTRACT

Background: Frozen shoulder is defined as the painful and disabling condition with unknown etiology. It has a limited shoulder range of motion due to decreased capsular flexibility and altered muscle function. Assessment on the frozen shoulder is needed, and it is vital to know the alteration in scapular muscles in the shoulder range of motion during arm elevation. The intention of conducting this study is to reach conclusions of tightness of a muscle in the upper trapezius, pectoralis minor muscle, and frozen shoulder levator scapulae showing limited ranges.

Methods: In this cross-sectional observational study, 50 subjects of age 30 and above were assessed for muscle length in the frozen shoulder and unaffected shoulder. Subjects with shoulder pain with frozen shoulder stage 2 and above are allotted into the affected shoulder, and unaffected shoulder; both groups were assessed. The following parameters were measured: ROM of the shoulder, SPADI ratings, short pectoral thickness, levator scapulae length, and upper trapezium muscle length.

Results: Decreased shoulder flexion, extension, abduction, and limited rotations were the problems associated with frozen shoulder. Pearson correlation coefficient for PMI and LSI shows Positive Correlation $r = 40.6\%$ on the affected side. Pearson correlation for PMI and UTI shows Positive Correlation $r = 13.4\%$. Pearson Correlation for LSI and UTI shows Positive Correlation $r = 28.1\%$ on the affected side.

Conclusion: There was a correlation between upper trapezius, levator scapulae, and pectoralis minor muscle length. Most of the affected side shoulder showed the tightness in the pectoralis minor muscle.

Keywords: pectoralis minor, levator scapulae, upper trapezius, frozen shoulder.

Received 19th January 2020, accepted 07th April 2020, published 09th April 2020



www.ijphy.org

10.15621/ijphy/2020/v7i2/659

CORRESPONDING AUTHOR

^{*1}Pranisa Vardanapu

Department of Physiotherapy,
Nizam's Institute of Medical Sciences,
Hyderabad, Telangana, India.
Email: pranisa1993@gmail.com

¹Department of Physiotherapy, Nizam's Institute of Medical Sciences, Hyderabad, Telangana, India.

²Department of Orthopaedics, Nizam's Institute of Medical Sciences, Hyderabad, Telangana, India.



INTRODUCTION

Frozen shoulder is a medical ailment in which the shoulder joint became rigid, and the movement is limited. Frozen shoulder mainly affects older individuals and is more common in females [1]. The average disease occurrence is 3% to 5%, with peak intensity between the ages of 35 and 65 years [2]. Frozen shoulder may be either essential idiopathic or secondary to a systemic infection. Clinically, patients experience a stage of pain, which leads to a freezing stage when glenohumeral movement is lost, followed by a thawing stage in which pain steadily subsides and most of the lost movement returns [3].

There will be significant deficits in shoulder kinematics in frozen shoulder patients, with more boost and mounting scapular rotation [4]. This scapular placing will affect the soft tissue such as periscapular muscle stubbornness and adjustment [5]. During the elevation of the arm, the normal scapular motions are restricted because of the tightness of the muscles of the soft tissue [6].

Main stabilizers of the scapulae include levator scapulae, anterior trapezius, major and minor rhomboids, and serratus. The group of scapular muscle works synergistically with the muscles of the spinner cuff to control the scapular movement [7]. The upper trapezius in the frozen shoulder appears heavily triggered than the lower trapezius, hence create the difference in scapular stabilizers [8].

The levator scapulae act to expand the scapula and to lower the glenoid cavity by moving the scapula downwards [9]. The small pectoral muscle works like a downward scapular rotator, an anterior tilter, and an internal rotator and is principally incompatible to the necessary scapulothoracic movements throughout arm elevation [10]. Researchers have recently begun studying scapular kinematics in disciplines with adhesive capsulitis or shoulder rigidity during humeral elevation [11].

The above studies have recognized significant upsurges in upward scapular turning on the affected side of subjects with adhesive capsulitis associated with their natural side [12]. Once stable subjects were identified as having a less resting time and a long pectoral period, those with a short pectoral slight evidence of muscle tightness showed slightly less scapular rear tilting. It increased the inner scapular movement during arm elevation [13].

Previous studies using the Pectoralis Minor Index (PMI) in both symptomatic and control groups reported dominant and non-dominant normative values [14]. The therapeutic outcome was usually measured in patients with frozen shoulder by active and/or passive ROM, self-administered shoulder questionnaires, subjective visual analog scale, or maximum voluntary contraction (MVC) [15]. It has been reported that pectoralis minor shortness in terms of its reliability has received remarkable attention.

However, there was no calculation difference between the impacted and natural frozen shoulder. The levator scapulae index between the affected and normal frozen

shoulder has not yet been tested to the best of our facts variances in the upper trapezius scale. The research thus attempts to calculate the length of the muscle and the relationship between the upper trapezius, the levator scapulae, and the length of the pectoralis minor muscle in phase 2 and above of the frozen shoulder relative to the non-affected shoulder. The study's objective was to check evidence of muscle tightness in levator scapulae, upper trapezius, and small pectoral muscle in frozen shoulder showing limited ranges. It has been hypothesized that in frozen shoulder stage 2 and above, there will be a correlation between the levator scapulae, upper trapezius and pectoralis minor alteration in the length of the muscle compared to the non-affected shoulder. While the study's null hypothesis is that there is no correlation between levator scapulae, upper trapezius and pectoralis minor changes in the length of the muscle in stage 2 and above of the frozen shoulder compared to the unaffected shoulder.

METHODOLOGY

Study design:

It was a cross-sectional review and was done after approval was received from the Institutional Ethics Committee.

Participants:

A group of 50 patients with a unilateral frozen shoulder was recruited. Subjects with a frozen shoulder that were directed to the physiotherapy department were screened to meet the inclusion criteria. Subjects with unilateral frozen shoulder stage 2 and above were included in the study and analyzed. All people have given consent to participate in the study.

The inclusion measures had to be met by the participants: males and females aged between 30 and above; unilateral frozen shoulder; frozen shoulder with stage 2 and above. Participants excluded from participating in this study: a history of pathological shoulder fractures, inflammatory disorders like rheumatoid arthritis, red flags signs comprise trauma, cancer, recent infection, a history of neurological problems.

Age, gender, height, and VAS were obtained in the study group and control group demographic details. In this study, the participants were analyzed using the index of Shoulder pain and weakness (SPADI), Pectoralis minor index, Shoulder range of motion, Upper trapezius index, Levator scapulae index.

Outcome measures:

The investigator takes all the measurements, including the height required to calculate LSI and PMI values.

Shoulder ROM: Motion Range of the shoulder was assessed using a goniometer.

SPADI: The effect is a self-administered device that would represent the discomfort and weakness involved with the painful shoulder.

Pectoralis Minor Index: It was calculated by the division of the resting length of the muscle by the height of the subject and multiplying by 100.

Levator Scapulae Index: The subject height calculates the LSI and the length of the levator scapulae is multiplied by 100.

Upper Trapezius Index: Linear measurement as an index of the upper muscular length of the trapezium will be influenced by the dimensions of the subject body and the flexibility of the neck.

Pectoralis minor muscle length test:

The participants stood upright with their test arm resting on their side to measure the length of the pectoral muscle. Then, by the investigator, the anatomical symbol will palpate and mark the reference points. The length of the resting muscle is determined by the inferomedial feature of the coracoid process with the Vernier caliper between the caudal edges of the 4th Ribas Borstad (2008) et al. described earlier [16]. In a standing position, the patient's height was measured by a caliper positioned at the head top, and a point indicated on a wall-mounted scale. A sliding clip was used to determine the length of the resting muscle from the caudal edge of the fourth rib to the inferomedial part of the coracoid procedure⁽¹³⁾.

Levator scapulae muscle length test:

The test procedure is performed in a standardized position with subjects on their sides with relaxed arms and legs apart. Subjects were instructed to restrict any craniocervical movements and to take muscle length after exhale and relaxed breathe condition. Then the examiner will palpate the anatomical landmarks and mark the reference points. The two points of reference are anatomical: (1) The second cervical vertebrae dorsal tubercles and transverse processes and (2) the upper spinal border angle of the scapula. To measure the distance between these bony reference points, a Vernier caliper was used. Through developing an LSI, the body height variation of the participants has been normalized. The LSI was articulated as a proportion of the subject height.

Upper trapezius muscle length test:

This is to map the muscle length of the upper trapezium involved by preserving the stretching and the complete contralateral extension of the cervical spine, and then the maximum contraction of the shoulder girdle. The padded head restraint maintained the area of the head and neck at the edge of the cervical lateral flexion of the subjects to standardize the test between subjects, supporting the head on the pillow or a 30-degree foam wedge cutting angle for cervical flexion. Then the anatomical points of reference should be palpated and marked. Using the Vernier caliper, the anatomical characteristics of the mastoid procedure and the acromioclavicular joint were measured in the extended condition of the trapezoid muscle [17].

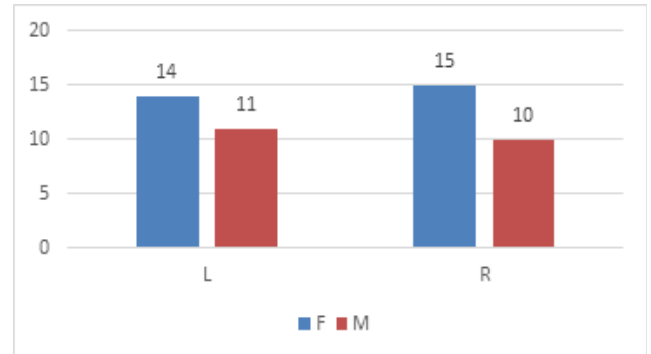
STATISTICAL ANALYSIS AND RESULTS:

Demographic features are the subjects' mean age was 50, with a standard deviation of 6.01. There were 29 females and 21 males in the study. The mean height of the subjects

was 157, with a standard deviation of 6.3, and the mean VAS of the subjects was 5.9, with a standard deviation of 1.1.

Count		SIDE		Total
		L	R	
GENDER	F	14	15	29
	M	11	10	21
Total		25	25	50

Table 1: Representation of the subjects in the study



Graph 1: Representation of the demographic data of the subjects

	N	Median	Standard deviation	Std. error mean
AGE	50	49.100	6.01444	.85057
HEIGHT	50	157.2800	6.35045	.89809
VAS	50	5.9800	1.13371	.16033

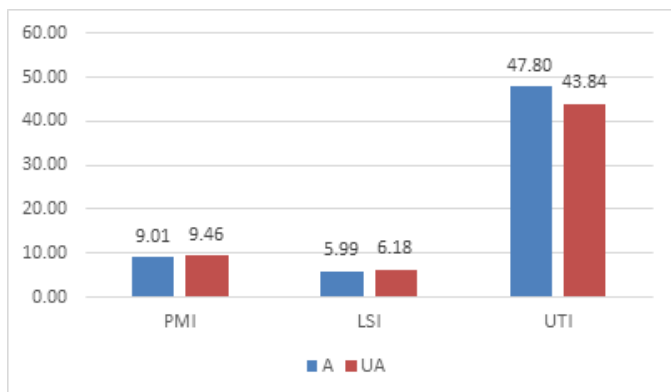
Table 2: Representation of the demographic data of the study

Mean values for the outcome measures:

Mean values for shoulder ROM has a significant difference in the affected and unaffected shoulder. There was a decrease in the shoulder ROM in the affected shoulder $p < 0.001$. The mean SPADI score for the affected shoulder was 53.1, and for the unaffected shoulder, it was 0. The mean values for PMI, LSI, and UTI are given in table no 1. There was a significant statistical difference between affected and unaffected shoulder examined by t-test. T value -2.943; the p-value is 0.04 below 0.05, while no statistical difference was found in LSI, UTI.

	Group	N	Mean	Std. Deviation	Std. Error
PMI	A	50	9.0080	.82902	.11724
	UA	50	9.4620	.70880	.10024
LSI	A	50	5.9920	.52947	.07488
	UA	50	6.1820	.64640	.09141
UTI	A	50	47.8000	11.39638	1.61169
	UA	50	43.8400	8.61029	1.21768

Table 3: Analysis of PMI, LSI, and UTI in the affected and unaffected shoulder

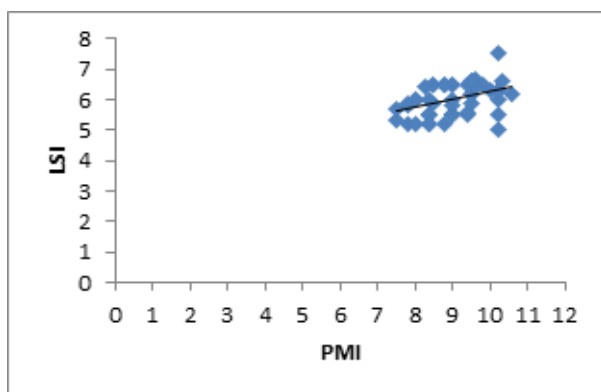


Graph 2: Representation the index of PMI, LSI, and UTI IN affected and unaffected shoulder

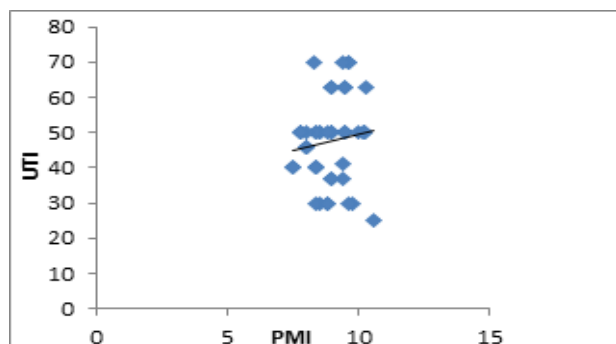
		PMI_A	LSI_A	UTI_A
PMI_A	Pearson's r	1	.406**	.134
	Sig. (2-tailed)		.003	.354
	N	50	50	50
LSI_A	Pearson's r	.406**	1	.281*
	Sig. (2-tailed)	.003		.048
	N	50	50	50
UTI_A	Pearson's r	.134	.281*	1
	Sig. (2-tailed)	.354	.048	
	N	50	50	50

Table 4: Representation of correlation between PMI, LSI, and UTI in the affected shoulder

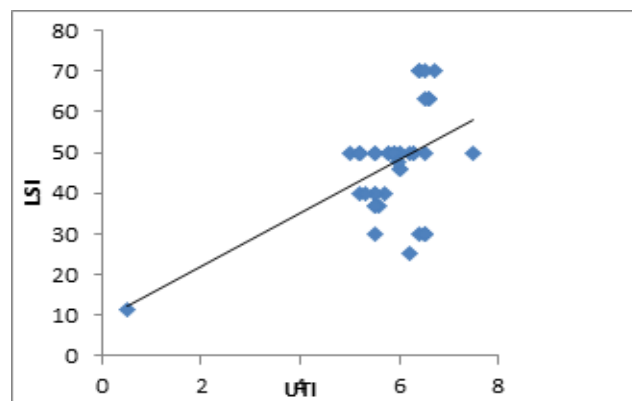
The correlation between them is on the table. The positive correlation present between the PMI and LSI, PMI and UTI, LSI, and UTI in affected shoulder analyzed by the Pearson Correlation test.



Graph 3: Represents the positive correlation between PMI and LSI in affected shoulder.



Graph 4: Represents the positive correlation between PMI and UTI in the affected shoulder



Graph 5: Representation of the positive correlation between UTI and LSI in the affected shoulder

DISCUSSION

The goal of the analysis is to investigate the association in the frozen shoulder between the upper trapezius, levator scapulae, and pectoralis minor muscle length relative to the non-affected shoulder. We found a significant statistical difference in the pectoralis minor muscle index between affected and unaffected shoulder; its p-value is 0.004, which is less than 0.05. We found no significant difference between in the upper trapezius and levator scapulae measure of the affected and unaffected shoulder, its p-value is 0.0053 and 0.111, which is greater than 0.05. In the current study, we observed that the bending, extension, abduction and rotation ranges of the affected side of the shoulder were significantly lower compared to the unaffected side, this could be due to the tightness of the shoulder capsule and the associated muscle ligament that may alter the shoulder joint's kinematics [18]. The results of this study demonstrate the association in the frozen shoulder between upper trapezius, levator scapulae, and size of the small pectoral muscle.

This is the first report that uses accessible and low-cost tools to correlate the upper trapezius, levator scapulae, and pectoralis minor muscle length in a frozen shoulder compared to the unaffected shoulder. In our analysis, we observed a substantial difference in the length and index of the small pectoral muscle in a frozen shoulder relative to the non-affected shoulder. The tight pectoral minor muscle associated with multiple shoulder pathologies and altered scapular patterns leading to scapular dyskinesia (Bostard et al. 2005) [13]. The tightness of the small and posterior pectoral shoulder during arm elevation prevents natural scapular mobility [6].

It has been reported that in patients with shoulder conditions, they have found an overactive upper trapezius muscle (Lin et al., 2005; Ludewig and Paula M et al., 2000) [8, 19]. However, our study found no statistical significance between the frozen shoulder and the unaffected shoulder in the upper trapezius muscle length and scale. The explanation is based on current and previous research that patients with frozen shoulder have had continuous shoulder pain for months, significantly longer pain, and more severe than shoulder or weakness impingement. Chronic pain may give rise to strong inhibition signals, leading to the

hypoactive upper trapeze. In the frozen shoulder patient, there was no statistical difference in the length of the levator scapulae between the affected shoulder and the unaffected shoulder. As far as we know, this is the first research to see an impacted and unaffected gap in the frozen shoulder, which makes it difficult to compare with others. In the previous study, the intra-and inter-rater consistency of LSI was investigated in subjects with and without scapular downward rotation syndrome and demonstrated excellent inter-rater reliability with and without SRDS and improved interrater reliability for subjects with SRDS. Short lever scapulae are assumed to create more rotating scapulae and more complex overhead movement [20]. The study results show that there is no statistical difference between LSI.

Pearson correlation coefficient, for PMI and LSI, shows Positive Correlation $r = 40.6\%$, for PMI and UTI shows Positive Correlation $r = 13.4\%$ and for LSI and UTI shows Positive Correlation $r = 28.1\%$ in the affected side. From this study, we have observed that there was a positive correlation between the levator scapulae, upper trapezius, and pectoralis minor muscle length in the frozen shoulder compared with an unaffected shoulder, which supports our hypothesis.

This cross-sectional observational study has shown a minimal change in the muscle length in the frozen shoulder and recommends corrections with proper exercises. Further research that analyses the length of the levator scapulae and upper trapezius, and scapular positioning in shoulder disorders.

CONCLUSION

In conclusion, there is a significant difference in the pectoralis minor index (PMI) in the frozen shoulder comparatively with unaffected shoulder and no significant difference in the upper trapezius and levator scapulae index in the frozen shoulder in comparison with an unaffected shoulder. There is a positive correlation among the upper trapezius, levator scapulae, and pectoralis minor muscle length in the frozen shoulder. Thus from the above results, the great significance is for the pectoralis minor index. Further studies analyzing the length of pectoralis minor after the implementation of physical therapies are required as an indicator of improvement in frozen shoulder.

LIMITATIONS

A short-duration study and less sample size were taken for the study. There is a postural alteration, and soft tissue contour during measurement may affect the results.

FUTURE SCOPE

Studies with long term follow up & larger sample size is recommended for generalization of the result. A homogenous sample with either male or female subjects could be taken separately for future studies. Further research that analyses scapular positioning along with muscle length measurement.

REFERENCES

[1] Shih Y F, Liao P W, Lee C S. The immediate effect of muscle release intervention on muscle activity

and shoulder kinematics in patients with frozen shoulder: a cross-sectional, exploratory study. *BMC musculoskeletal disorders*. 2017;18(1):499.

- [2] Inayat F, Ali N S, Shahid H, Younus F. Prevalence and determinants of frozen shoulder in patients with diabetes: a single center experience from Pakistan. *Cureus*. 2017;9(8).
- [3] Milgrom C, Novack V, Weil Y, Jaber S, Radeva-Petrova DR, Finestone A. Risk factors for idiopathic frozen shoulder. *The Israel Medical Association Journal*. 2008;10(5):361.
- [4] Rundquist PJ, Anderson DD, Guanche CA, Ludewig PM. Shoulder kinematics in subjects with frozen shoulder. *Archives of physical medicine and rehabilitation*. 2003;84(10):1473–1479.
- [5] Kibler WB, Ludewig PM, McClure PW, Michener LA, Bak K, Sciascia AD. Clinical implications of scapular dyskinesis in shoulder injury: the 2013 consensus statement from the ‘Scapular Summit.’ *Br J Sports Med*. 2013;47(14):877–885.
- [6] Borich MR, Bright JM, Lorello DJ, Cieminski CJ, Buisman T, Ludewig PM. Scapular angular positioning at end range internal rotation in cases of glenohumeral internal rotation deficit. *Journal of Orthopaedic & Sports Physical Therapy*. 2006;36(12):926–934.
- [7] Yano Y, Hamada J, Tamai K, Yoshizaki K, Sahara R, Fujiwara T et al. Different scapular kinematics in healthy subjects during arm elevation and lowering: glenohumeral and scapulothoracic patterns. *Journal of shoulder and elbow surgery*. 2010;19(2):209–215.
- [8] Lin JJ, Wu YT, Wang SF, Chen SY. Trapezius muscle imbalance in individuals suffering from frozen shoulder syndrome. *Clinical rheumatology*. 2005;24(6):569–575.
- [9] Paine R, Voight ML. The role of the scapula. *International journal of sports physical therapy*. 2013;8(5):617.
- [10] Phadke V, Camargo PR, Ludewig PM. Scapular and rotator cuff muscle activity during arm elevation: a review of normal function and alterations with shoulder impingement. *Brazilian Journal of Physical Therapy*. 2009;13(1):1–9.
- [11] Fayad F, Roby-Brami A, Yazbeck C, Hanneton S, Lefevre-Colau MM, Gautheron V, et al. Three-dimensional scapular kinematics and scapulohumeral rhythm in patients with glenohumeral osteoarthritis or frozen shoulder. *Journal of biomechanics*. 2008;41(2):326–332.
- [12] Rundquist PJ. Alterations in scapular kinematics in subjects with idiopathic loss of shoulder range of motion. *Journal of orthopaedic & sports physical therapy*. 2007;37(1):19–25.
- [13] Borstad JD, Ludewig PM. The effect of long versus short pectoralis minor resting length on scapular kinematics in healthy individuals. *Journal of orthopaedic & sports physical therapy*. 2005;35(4):227–238.
- [14] Struyf F, Meeus M, Franssen E, Roussel N, Jansen N, Truijfen S, et al. Interrater and intrarater reliability of

-
- the pectoralis minor muscle length measurement in subjects with and without shoulder impingement symptoms. *Manual therapy*. 2014;19(4):294–298.
- [15] Sokk J, Gapeyeva H, Ereline J, Kolts I, Pääsuke M. Shoulder muscle strength and fatigability in patients with frozen shoulder syndrome: the effect of 4-week individualized rehabilitation. *Electromyography and clinical neurophysiology*. 2007;47(4-5):205–213.
- [16] Borstad J D. Measurement of pectoralis minor muscle length: validation and clinical application *journal of orthopaedic & sports physical therapy*. 2008;38(4):169–174.
- [17] Sutton S. The relationship between upper trapezius muscle length and upper quadrant neural tissue extensibility. *Physiotherapy*. 1994;40:99–103.
- [18] jenq Lin J, Lim HK, Yang JL. Effect of shoulder tightness on glenohumeral translation, scapular kinematics, and scapulohumeral rhythm in subjects with stiff shoulders. *Journal of Orthopaedic Research*. 2006;24(5):1044–1051.
- [19] Ludewig PM, Cook TM. Alterations in shoulder kinematics and associated muscle activity in people with symptoms of shoulder impingement. *Physical therapy*. 2000;80(3):276–291.
- [20] LeeJH, CynnHS, ChoiWJ, JeongHJ, YoonTL. Reliability of levator scapulae index in subjects with and without scapular downward rotation syndrome. *Physical Therapy in Sport*. 2016;19:1–6.